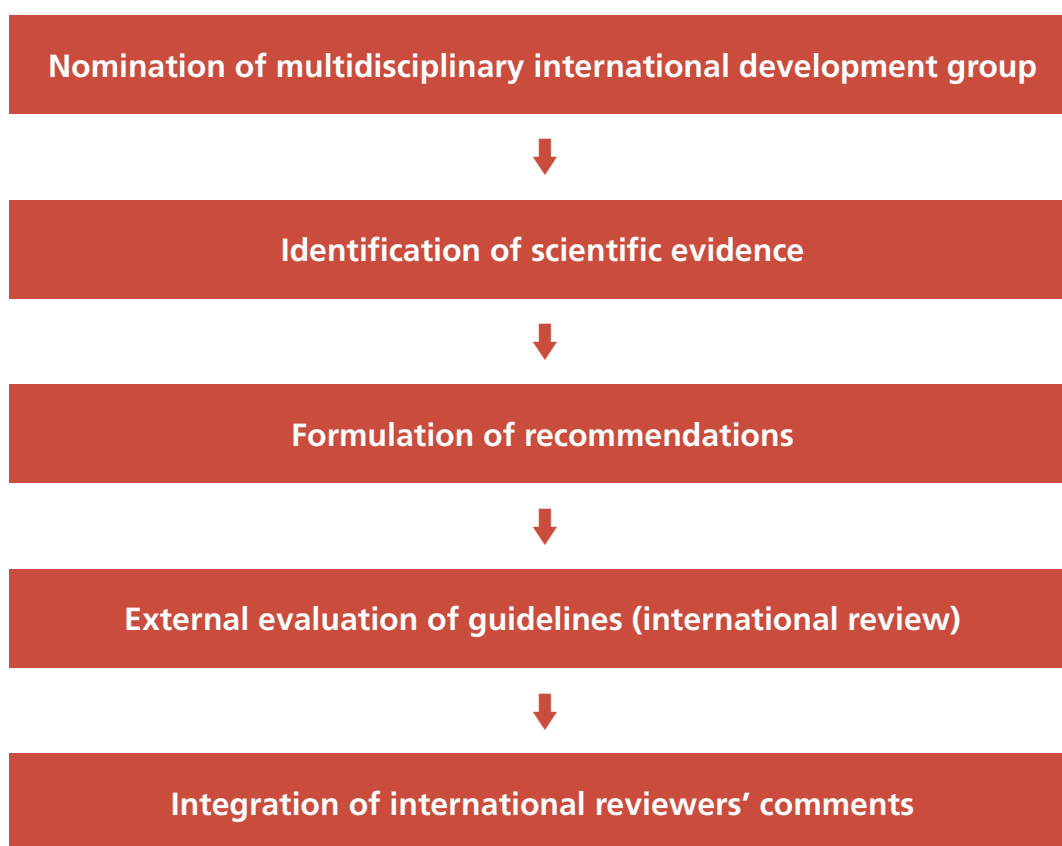


VULVAR CANCER GUIDELINES



The European Society of Gynaecological Oncology (ESGO) developed guidelines covering diagnosis and referral, preoperative investigations, surgical management (local treatment, groin treatment, reconstructive surgery), sentinel lymph node procedures, radiation therapy, chemoradiation, systemic treatment, treatment of recurrent disease (vulvar recurrence, groin recurrence, distant metastases), and follow-up for patients with vulvar cancer.

A five-step development process followed:



The objectives of these guidelines are to improve and to homogenise the management of patients with vulvar cancer. The guidelines are intended for use by gynaecological oncologists, general gynaecologists, surgeons, pathologists, radiotherapists, medical and clinical oncologists, general practitioners, palliative care teams, and allied health professionals.

These guidelines apply to adults over the age of 18 who have squamous cell carcinoma of the vulva. These guidelines do not address patients with other vulvar cancer histologies. Any clinician seeking to apply or consult these guidelines is expected to use independent medical judgment in the context of individual clinical circumstances to determine any patient's care or treatment.

To ensure that the statements made in this document are evidence-based, the current literature was reviewed and critically appraised. A comprehensive literature review of the studies published between January 1980 and September 2015 was carried out.

The guidelines were retained if they were supported by sufficient high-level scientific evidence and/or when a large consensus among experts was obtained. By default, a clinical approach guideline is defined as being the criterion-standard clinical approach. If an approach is judged to be acceptable but is not unanimously recognized as a criterion-standard clinical approach, indication is given that it is still subject to discussion and/or evaluation.

These guidelines have five different “strength of guideline” ratings (SIGN grading system¹):

A At least one meta-analysis, systematic review, or RCT rated as 1++, and directly applicable to the target population; or

A body of evidence consisting principally of studies rated as 1+, directly applicable to the target population, and demonstrating overall consistency of results

B A body of evidence including studies rated as 2++, directly applicable to the target population, and demonstrating overall consistency of results; or

Extrapolated evidence from studies rated as 1++ or 1+

C A body of evidence including studies rated as 2+, directly applicable to the target population and demonstrating overall consistency of results; or

Extrapolated evidence from studies rated as 2++

D Evidence level 3 or 4; or

Extrapolated evidence from studies rated as 2+

✓ Recommended best practice based on the clinical experience of the guideline development group

1++ high quality meta-analyses, systematic reviews of randomised controlled trials (RCTs), or RCTs with a very low risk of bias; 1+ well conducted meta-analyses, systematic reviews, or RCTs with a low risk of bias; 2++ high quality systematic reviews of case control or cohort studies/high quality case control or cohort studies with a very low risk of confounding or bias and a high probability that the relationship is causal; 2+ well conducted case control or cohort studies with a low risk of confounding or bias and a moderate probability that the relationship is causal; 3 non-analytic studies, e.g. case reports, case series; 4 expert opinions.

¹ <http://www.sign.ac.uk/guidelines/fulltext/50/annexoldb.html>

PREOPERATIVE INVESTIGATIONS



In any patient suspected for vulvar cancer, diagnosis should be established by a punch/incision biopsy. Excision biopsy should be avoided for initial diagnosis, as this may obstruct further treatment planning.



In patients with multiple vulvar lesions, all lesions should be biopsied separately (with clear documentation of mapping).



All patients with vulvar cancer should be referred to a Gynaecological Oncology Centre (GOC) and treated by a multidisciplinary gynaecological oncology team.

STAGING SYSTEM



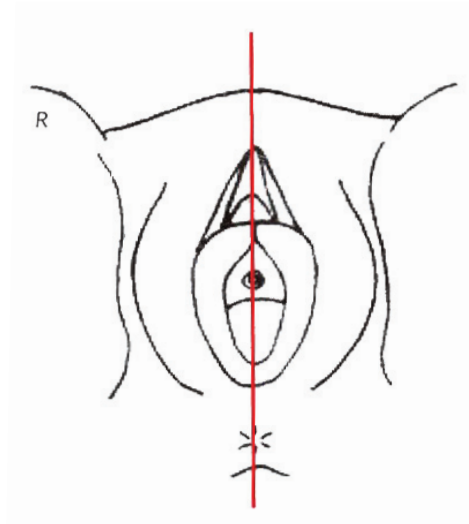
Vulvar cancer should be staged according to FIGO and/or TNM classification².

² Throughout these recommendations, advanced stage of disease is defined as clinical T3 and/or N3.

PREOPERATIVE INVESTIGATIONS



Preoperative work-up should at least include clear documentation of the clinical exam (size of lesion, distance to the midline/clitoris/anus/vagina/urethra and palpation of lymph nodes). Picture or clinical drawing is advised (see below).



Evaluation of the cervix/vagina/anus is recommended.



Prior to sentinel lymph node biopsy, clinical examination and imaging of the groins, (either by ultrasound, (positron emission tomography-) computed tomography ((PET-) CT), or magnetic resonance imaging (MRI)) are required to identify potential lymph node metastases.



Suspicious nodes (at palpation and/or imaging) should be analysed by fine-needle aspiration (FNA), or core biopsy when this would alter primary treatment.



Further staging with CT thorax/abdomen and pelvis is recommended where there is a clinical suspicion of, or proven, (nodal) metastatic disease and/or advanced stage disease.



The pathology report on preoperative biopsy should at least include histological type and depth of invasion.

SURGICAL MANAGEMENT

Groin treatment

| | |
|----------|---|
| C | Radical local excision is recommended. |
| ✓ | Consider additional, more superficial resection of differentiated vulvar intraepithelial neoplasia (d-VIN) in addition to radical local excision of invasive tumours. |
| ✓ | In multifocal invasive disease, radical excision of each lesion as a separate entity may be considered. Vulvectomy may be required in cases with multifocal invasion arising on a background of extensive vulvar dermatosis. |
| ✓ | The goal of excision is to obtain tumour-free pathological margins. Surgical excision margins of at least 1 cm are advised. It is acceptable to consider narrower margins where the tumour lies close to midline structures (clitoris, urethra, anus), and preservation of their function is desired. |
| ✓ | When invasive disease extends to the pathological excision margins of the primary tumour, reexcision is the treatment of choice. |
| ✓ | The optimal management of the groin (full inguinofemoral lymphadenectomy or isolated removal only) for enlarged, proven metastatic nodes remains to be defined. |

Groin treatment

| | |
|----------|--|
| C | Groin treatment should be performed for tumours > pT1a. |
| B | For unifocal tumours < 4 cm without suspicious groin nodes on clinical examination and imaging (any modality) the sentinel lymph node procedure is recommended. |
| C | For tumours \geq 4 cm and/or in case of multifocal invasive disease, inguinofemoral lymphadenectomy by separate incisions is recommended. In lateral tumours (medial border > 1 cm from midline), ipsilateral inguinofemoral lymphadenectomy is recommended. Contralateral inguinofemoral lymphadenectomy may be performed when ipsilateral nodes show metastatic disease. |
| D | When lymphadenectomy is indicated, superficial and deep femoral nodes should be removed. |
| C | Preservation of the saphenous vein is recommended. |
| ✓ | The optimal management of the groin (full inguinofemoral lymphadenectomy or isolated removal only) for enlarged, proven metastatic nodes remains to be defined. |
| ✓ | Where enlarged (> 2 cm) pelvic nodes are identified, their removal should be considered. |

Reconstructive surgery



Availability of reconstructive surgical skills as part of the multidisciplinary team is required in early as well as advanced stage disease.

SENTINEL LYMPH NODE PROCEDURE

B

The sentinel lymph node procedure is recommended in patients with unifocal cancers of < 4 cm, without suspicious groin nodes.

B

Use of radioactive tracer is mandatory; use of blue dye is optional.

C

Lymphoscintigram is advised to enable the preoperative identification, location, and number of sentinel lymph nodes.

C

Intraoperative evaluation and/or frozen sectioning of the sentinel lymph node can be performed in an attempt to prevent a second surgical procedure. Caution is warranted because of an increased risk of missing micrometastases on final pathology due to the loss of tissue arising from processing for frozen section assessment.



When a sentinel lymph node is not found (method failure), inguofemoral lymphadenectomy should be performed.

C

Where metastatic disease is identified in the sentinel lymph node (any size): inguofemoral lymphadenectomy in the groin with the metastatic sentinel lymph node.



For tumours involving the midline: bilateral sentinel lymph node detection is mandatory. Where only unilateral sentinel lymph node detection is achieved, an inguofemoral lymphadenectomy in the contralateral groin should be performed.

C

Pathological evaluation of sentinel lymph nodes should include serial sectioning at levels of at least every 200 µm. If the H&E sections are negative, immunohistochemistry should be performed.

RADIATION THERAPY

- ✓ Adjuvant radiotherapy should start as soon as possible, preferably within 6 weeks of surgical treatment.
- ✓ When invasive disease extends to the pathological excision margins of the primary tumour, and further surgical excision is not possible, postoperative radiotherapy should be performed.
- ✓ In case of close but clear pathological margins, postoperative vulvar radiotherapy may be considered to reduce the frequency of local recurrences. There is no consensus for the threshold of pathological margin distance below which adjuvant radiotherapy should be advised.
- B** Postoperative radiotherapy to the groin is recommended for cases with > 1 metastatic lymph node and/or the presence of extracapsular lymph node involvement.
- ✓ Adjuvant radiotherapy for metastatic groin nodes should include the ipsilateral groin area and where pelvic nodes are non-suspicious on imaging, the distal part of the iliac nodes with an upper limit at the level of the bifurcation of the common iliac artery.
- C** Based on evidence from other squamous cell cancers such as cervical, head & neck, and anal cancer, the addition of concomitant, radiosensitising chemotherapy to adjuvant radiotherapy should be considered.

CHEMORADIATION

- C** Definitive chemoradiation (with radiation dose escalation) is the treatment of choice in patients with unresectable disease.
- C** In advanced stage disease, neoadjuvant chemoradiation should be considered in order to avoid exenterative surgery.
- C** Radiosensitising chemotherapy, preferably with weekly cisplatin, is recommended.

SYSTEMIC TREATMENT

- D** Data in vulvar cancer are insufficient to recommend a preferred schedule in a palliative setting.

TREATMENT OF RECURRENT DISEASE

Treatment of vulvar recurrence



Radical local excision is recommended.



For vulvar recurrence with a depth of invasion > 1 mm and previous sentinel lymph node removal only, inguinofemoral lymphadenectomy should be performed.



The indications for postoperative radiotherapy are comparable to those for the treatment of primary disease.

Treatment of groin recurrence



Restaging by CT (or PET-CT) of the thorax/abdomen/pelvis is recommended.



Preferred treatment is radical excision when possible, followed by postoperative radiation in radiotherapy naïve patients.



Based on evidence from other squamous cell cancers, such as cervical and anal cancer, the addition of radiosensitising chemotherapy to postoperative radiotherapy should be considered.



Definitive chemoradiation when surgical treatment is not possible.

Treatment of distant metastases



Systemic (palliative) therapy may be considered in individual patients (see systemic treatment).

FOLLOW-UP



The optimal follow-up schedule for vulvar cancer is undetermined.



After primary surgical treatment, a follow-up schedule is suggested:

- First follow-up, 6-8 weeks postoperative
- First two years, every 3-4 months
- Third and fourth year, biannually
- Afterward, long-term follow-up, especially in case of predisposing vulvar disease.

Follow-up after surgical treatment should include clinical examination of vulva and groins.³



After definitive (chemo)radiation, the following follow-up schedule is suggested:

- First follow-up visit, 10-12 weeks post completion of definitive (chemo)radiation.
- First two years, every three-four months
- Third and fourth year, biannually
- Afterward, long-term follow-up, especially in case of predisposing vulvar disease.

At the first follow-up visit 10-12 weeks post definitive (chemo)radiation, CT or PET-CT is recommended to document complete remission.

³ Despite the well-recognised low sensitivity of palpation to identify groin recurrences, currently available data do not support routine use of imaging of the groins in follow-up.

ESGO would like to thank the international development group for their constant availability, work, and for making possible the development of these guidelines for patients with vulvar cancer. ESGO is also very grateful to the 181 international external reviewers for their participation (list available on the ESGO website).

ESGO also wishes to express its sincere gratitude to the French National Cancer Institute for providing the main funding for this work.

| Name | Specialty | Affiliation |
|------------------------|------------------------------------|--|
| Ate van der Zee | Gynaecologic Oncologist (chair) | University Medical Center, Groningen (Netherlands) |
| Maaïke Oonk | Gynaecologic Oncologist (co-chair) | University Medical Center, Groningen (Netherlands) |
| François Planchamp | Methodologist | Institut Bergonié, Bordeaux (France) |
| Peter Baldwin | Gynaecologic Oncologist | Addenbrooke's Hospital, Cambridge (United Kingdom) |
| Mariusz Bidzinski | Gynaecologic Oncologist | Holycross Oncology Center, Kielce (Poland) |
| Mats Brännström | Gynaecologic Oncologist | University of Gothenburg, Gothenburg (Sweden) |
| Fabio Landoni | Gynaecologic Oncologist | European Institute of Oncology, Milan (Italy) |
| Sven Mahner | Gynaecologic Oncologist | Ludwig Maximilian University of Munich, Munich (Germany) |
| Sergio Martinez | Gynaecologic Oncologist | Hospital Clinic of Barcelona, Barcelona (Spain) |
| Umesh Mahantshetty | Radiation Oncologist | Tata Memorial Hospital, Mumbai (India) |
| Mansoor Mirza | Medical Oncologist | Finsen Centre, Rigshospitalet, Copenhagen (Denmark) |
| Cordula Petersen | Radiation Oncologist | University Medical Center Hamburg, Hamburg (Germany) |
| Sigrid Regauer | Pathologist | Medical University of Graz, Graz (Austria) |
| Lukas Rob | Gynaecologic Oncologist | Charles University, Prague (Czech Republic) |
| Roman Rouzier | Surgeon | Pierre and Marie Curie University, Paris (France) |
| Elena Ulrikh | Gynaecologic Oncologist | N.N Petrov Research Institute of Oncology, St. Petersburg (Russia) |
| Jacobus van der Velden | Gynaecologic Oncologist | Academic Medical Center, Amsterdam (Netherlands) |
| Ignace Vergote | Gynaecologic Oncologist | University Hospital Leuven, Leuven (Belgium) |
| Linn Woelber | Gynaecologic Oncologist | University Medical Center Hamburg, Hamburg (Germany) |



European Society of
Gynaecological Oncology

ESGO Office
7, Rue Francois-Versonnex
1211 Geneva 6, Switzerland
Email: adminoffice@esgomail.org
www.esgo.org

© 2018 European Society of Gynaecological Oncology. All rights reserved.



The European Voice of Gynaecological Oncology